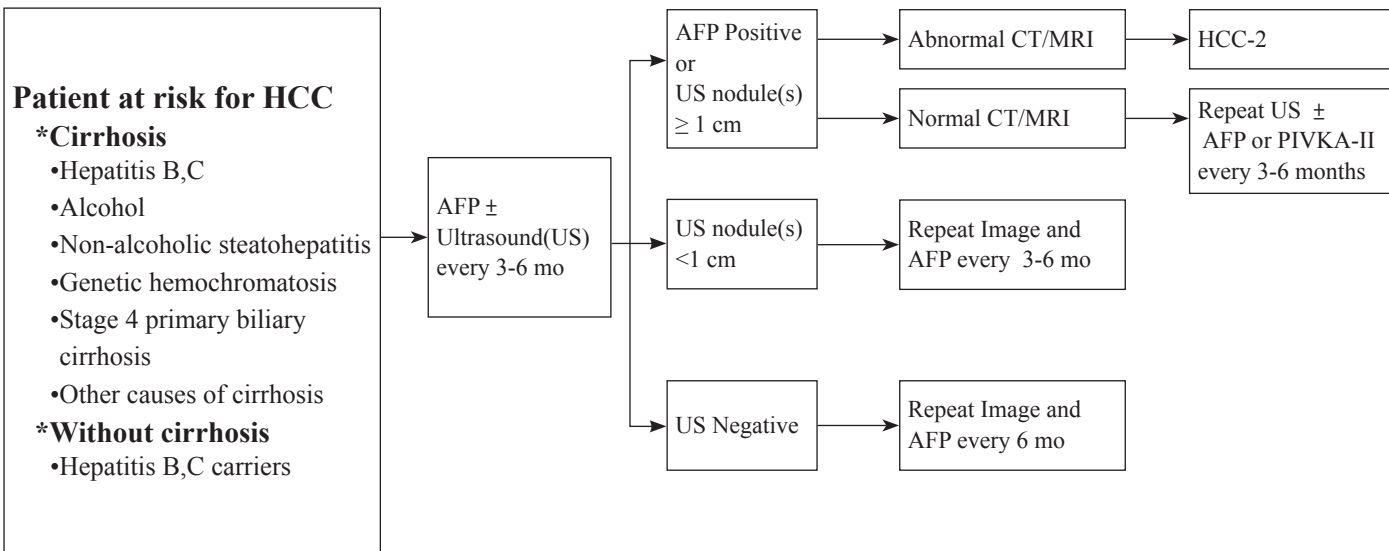


The background features a light gray gradient with several overlapping geometric shapes. A large, light gray diamond is centered, with a smaller, darker gray diamond to its left. A white diamond is also present, overlapping the light gray one. Faint, semi-transparent circles are scattered in the background.

Hepatocellular Cancers

《 HCC-1 》

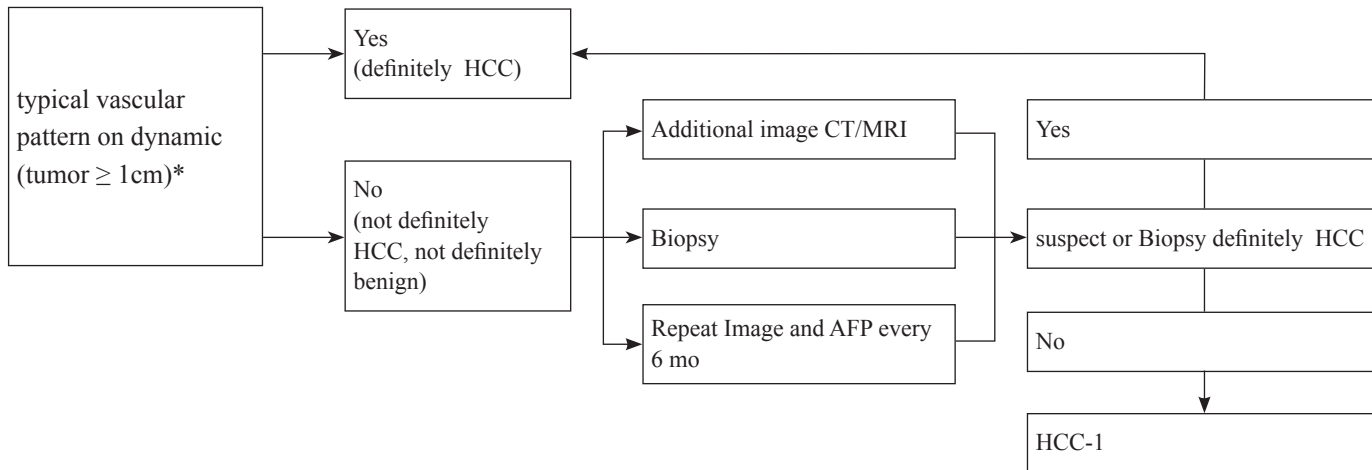
Evaluation high risk of HCC



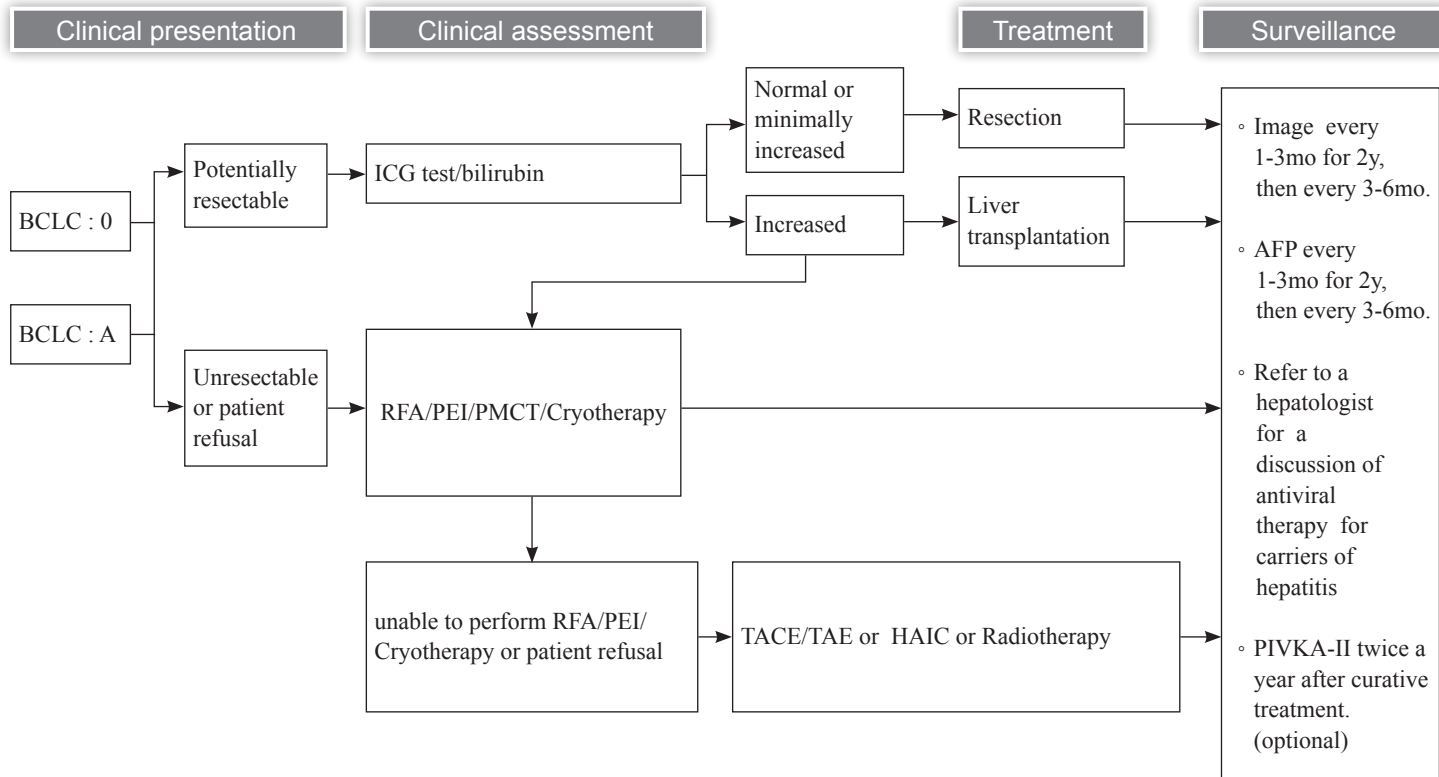
* TLCA 2023 reference suggest Cirrhosis•Hepatitis B,C 可增加用 PIVKA-II 追蹤

《 HCC-2 》

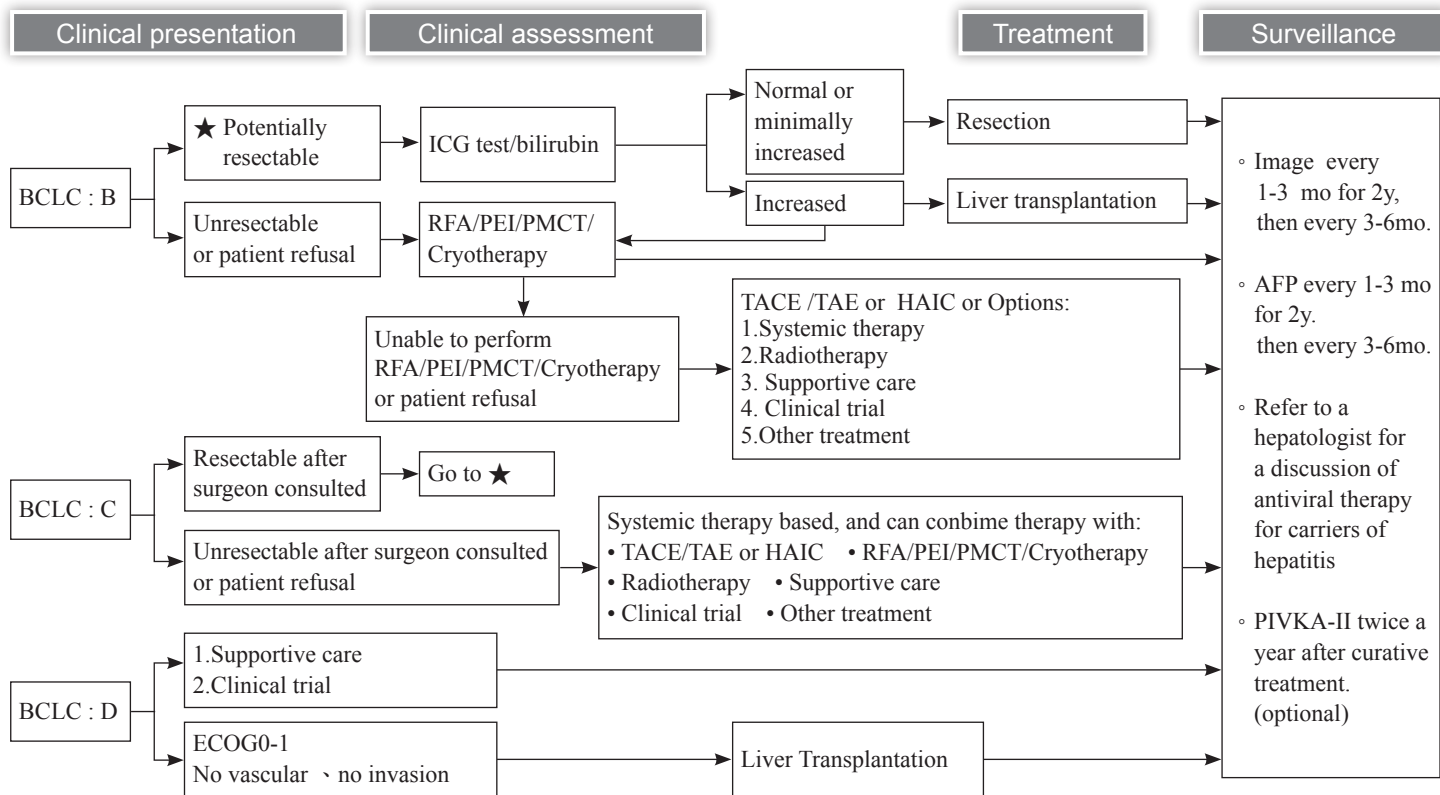
Clinical presentation



*in liver cirrhosis or hepatitis B carriers



《 HCC-4 》



1. NCCN Clinical Practice Guidelines in Oncology Hepatobiliary Cancers. V3. 2024.
2. Jordi Bruix, and Morries Sherman. Mangement of Hepatocellular Carcinoma,AASLD PRACTICE GUIDELINE . HEPATOLOGY , Vol.42, No. 5,2005.
3. Francois Durand, M.D., and Dominique Valla, M.D. Assessment of Prognosis of Cirrhosis. SEMINARS IN DISEASE, 2008;Vol.28, No.1:110-122.
4. Deniela Benedeto-Stojanov, Aleksandar Nagorni, et al.The Model for the End-Stage Liver Disease and Child-Pugh score in predicting prognosis in patients with liver cirrhosis and esophageal variceal bleeding. VOJNOSANITETSKI PREGLED 2009;Vol.66:724-728.
5. Mazzaferro V, et al. Liver transplantation for the treatment of small hepatocellular carcinomas in patients with cirrhosis. N Engl J Med. 1996 Mar 14;334(11):693-9.
6. Duffy JP et al. Liver transplantation criteria for hepatocellular carcinoma should be expanded: a 22-year experience with 467 patients at UCLA. Ann Surg. 2007 Sep;246(3):502-9; discussion 509-11.
7. Yamakado, K., et al., Early-stage hepatocellular carcinoma: radiofrequency ablation combined with chemoembolization versus hepatectomy. Radiology 2008; 247(1):260-266.
8. Maluccio, M.A., et al., Transcatheter arterial embolization with only particles for the treatment of unresectable hepatocellular carcinoma. J Vasc Interv Radiol 2008;19(6):862-869.
9. Kulik, L.M., et al., Safety and efficacy of 90Y radiotherapy for hepatocellular carcinoma with and without portal vein thrombosis. Hepatology 2008;47(1):71-81.
10. Cardenes HR, Price TR, Perkins SM, et al. Phase I feasibility trial of stereotactic body radiation therapy for primary hepatocellular carcinoma. Clin Transl Oncol 2010; 12:18-225.
11. Tse RV, Hawkins M, Lockwood G, K, et al. Phase I study of individualized stereotactic body radiotherapy for hepatocellular carcinoma and intrahepatic cholangiocarcinoma. J Clin Oncol 2008 26:657-664.
12. Hawkins MA, Dawson LA. Radiation therapy for hepatocellular carcinoma.Cancer 2006;106(8):1653-1663.

13. Tse RV, Guha C, Dawson LA. Conformal radiotherapy for hepatocellular carcinoma. *Crit Rev Oncol/Hematol* 2008;67:113-123.
14. Huang YJ, Hsu HC, Wang CY, et al. The treatment responses in cases of radiation therapy to portal vein thrombosis in advanced hepatocellular carcinoma. *IJROBP* 2009;73(4):1155-1163.
15. Meng MB, Cui YL, Lu Y, She B, Chen Y, Guan YS, et al. Transcatheter arterial chemoembolization in combination with radiotherapy for unresectable hepatocellular carcinoma: a systematic review and meta-analysis. *Radiotherapy and oncology : journal of the European Society for Therapeutic Radiology and Oncology*. 2009; 92(2): 184-94.
16. Seong J, Park HC, Han KH, Chon CY. Clinical results and prognostic factors in radiotherapy for unresectable hepatocellular carcinoma: a retrospective study of 158 patients. *Int J Radiat Oncol Biol Phys*. 2003; 55(2): 329-36.
17. Prof. M. kudo :Clinical Practice Guidelines for HCC Differ between Japan, United States, and Europe. *Liver Cancer* 2015;4:89-95
18. Eric C. H. et al: Spontaneous Rupture of Hepatocellular Carcinoma. *ARCH SURG/VOL* 141: 191-198, FEB 2006
19. Chi-leung Liu et al: Management of Spontaneous Rupture of Hepatocellular Carcinoma: Single-Center Experience. *Journal of Clinical Oncology*, Vol 19, No 17 (September 1): 3725-3732, 2001
20. Joon Sung Kim et al: Long-Term Survival in a Patient With Ruptured Hepatocellular Carcinoma. *The Korean Journal of Internal Medicine* Vol. 24, No. 1, March:63-67, 2009
21. Chiung-Yu Chen et al: Spontaneous Rupture of Hepatocellular Carcinoma – A Review of 141 Taiwanese Cases and Comparison with Nonrupture Cases.
22. Miyamoto M, et al: Spontaneous rupture of hepatocellular carcinoma: A review of 172 Japanese cases. *Am J Gastroenterol* 86:67-71, 1991
23. Paolo Sammartino et al: Prevention of Peritoneal Metastases from Colon Cancer in High-Risk Patients: Preliminary Results of Surgery plus Prophylactic HIPEC. *Gastroenterology Research and Practice* Volume 2012 (2012), Article ID 141585, 7 pages
24. Jesslyn H Ding et al: Hepatocellular Carcinoma Peritoneal Metastases: Report of Three Cases and Collective Review of the Literature. *Ann Acad Med Singapore* 2010;39:734-37
25. AASLD 2010 HCC Update .Jordi Bruix¹ and Morris Sherman²: Management of Hepatocellular Carcinoma: An Update. *HEPATOLOGY*, Vol. 000, No. 000, 2010

26. EASL–EORTC Clinical Practice Guidelines: Management of hepatocellular carcinoma: European Association for the Study of the Liver , European Organisation for Research and Treatment of Cancer. *Journal of Hepatology* 2012 vol. 56 j 908–943
27. Omata M, Cheng AL, Kokudo N, et al. Asia-Pacific clinical practice guidelines on the management of hepatocellular carcinoma: a 2017 update, *Hepatol Int* 2017;11(4):317-370.
28. Shao YY, Wang SY, Lin SM, Diagnosis G, Systemic Therapy G. Management consensus guideline for hepatocellular carcinoma: 2020 update on surveillance, diagnosis, and systemic treatment by the Taiwan Liver Cancer Association and the Gastroenterological Society of Taiwan. *J Formos Med Assoc* 2021; 120(4): 1051-1060.